

# Soft-Tissue Augmentation in Periodontally Compromised Patients during Immediate Placement and Immediate Loading Dental Implant Surgery - A Retrospective Study

Aleksandar Lazarov<sup>1,2,3</sup>

<sup>1</sup>Department of Research and Evidence, International Implant Foundation, Munich, Germany, <sup>2</sup>Department of Prosthodontics, Jaipur Dental College, Maharaj Vinayak Global, Jaipur, Rajasthan, India, <sup>3</sup>Private Oral Implant Center ALDENTAL, Sofia, Bulgaria

## Abstract

**Introduction:** The purpose of this article is to describe a soft-tissue augmentation procedure for multiple tooth extraction sites during immediate placement and immediate loading (IPIL) dental implant surgery in periodontally compromised patients and to present follow-up results of its effectiveness. **Methods:** A retrospective study was conducted on data from patients who underwent IPIL dental implant surgery between 2018 and 2021 at an oral implant centre in Bulgaria. Based on inclusion and exclusion criteria, 103 patients were included, 53 of whom had pre-operative indications for connective tissue grafts (CTGs) and 50 of whom did not. The post-operative incidence of gum recession was evaluated in the two patient groups. **Results:** The majority of the 53 patients (56.60%) had six, seven or eight tooth sites grafted. A significant proportion (87%) needed CTGs at the canine teeth (13 and 23),  $P < 0.001$ . The post-operative data showed a low incidence of gum recessions in both the patient groups, with a lower rate in the CTG group at tooth no: 13 (2.20% vs. 18%,  $P = 0.016$ ) and in the total sum of 10 tooth sites with CTGs ( $P = 0.001$ ). A reduction in gum problems and increased satisfaction with gum health and aesthetics were reported by 100% of the CTG patients. **Discussion:** Soft-tissue augmentation at multiple tooth extraction sites during IPIL dental implant treatment may benefit periodontally compromised patients through an improved prosthesis–tissue interface in the aesthetic area and a reduction in gum infections, swelling, bleeding and pain.

**Keywords:** Dental aesthetics, dental implants, gum disease, immediate placement and immediate loading protocols, soft-tissue augmentation

## INTRODUCTION

Dimensional bone and soft-tissue changes after tooth extraction are important factors to consider in dental implantology to achieve desired aesthetic outcomes.<sup>[1]</sup> Following the removal of all teeth in an adult, alveolar process atrophy and hard-tissue reduction occur.<sup>[2,3]</sup> The bundle bone at the site loses function and eventually disappears.<sup>[4-6]</sup> Most bone loss occurs in the horizontal dimension, primarily on the alveolar ridge's facial aspect. There is also a loss of vertical ridge height, which is most noticeable in the buccal aspect.<sup>[5,7,8]</sup> When the alveolus has lost walls or height, the situation becomes even more precarious.<sup>[9,10]</sup>

With the growing importance of aesthetics in dental treatment over the last decade, resorption of the alveolar ridge following multiple tooth extractions, particularly in

the anterior region, has become a significant problem.<sup>[11]</sup> The difficulties are exacerbated in immediate placement and immediate loading (IPIL) protocols, where adequate alveolar bone volume and favourable alveolar ridge architecture are required to achieve optimal functional and aesthetic implant-prosthetic reconstructions that blend with the adjacent natural structures.

**Address for correspondence:** Dr. Aleksandar Lazarov,  
No. 3 Solunska Street, Sofia 1000, Bulgaria.  
E-mail: alex.lazarov@yahoo.co.uk

**Received:** 11-11-2022

**Last Revised:** 13-01-2023

**Accepted:** 15-03-2023

**Published:** 02-06-2023

This is an open access journal, and articles are distributed under the terms of the Creative Commons Attribution-NonCommercial-ShareAlike 4.0 License, which allows others to remix, tweak, and build upon the work non-commercially, as long as appropriate credit is given and the new creations are licensed under the identical terms.

**For reprints contact:** WKHLRPMedknow\_reprints@wolterskluwer.com

**How to cite this article:** Lazarov A. Soft-tissue augmentation in periodontally compromised patients during immediate placement and immediate loading dental implant surgery - A retrospective study. *Ann Maxillofac Surg* 0;0:0.

### Access this article online

Quick Response Code:



**Website:**  
<https://journals.lww.com/aoms>

**DOI:**  
10.4103/ams.ams\_207\_22

According to animal and human studies, immediate implant placement into extraction sockets does not prevent socket dimensional changes after tooth extraction.<sup>[4]</sup> It has been suggested that a minimum width of 1–2 mm of buccal bone is required to keep the alveolar crest vertically stable.<sup>[12]</sup> The majority of extraction sites in the anterior maxilla have thin (or = 1 mm) buccal walls.<sup>[13]</sup> Thin and keratinised mucosa, advanced periodontitis and traumatic extractions, particularly of canines, are determining factors for soft-tissue augmentations.<sup>[14]</sup>

There are different periodontal plastic surgical techniques, of which subepithelial connective tissue graft and guided tissue regeneration are the current treatments of choice.<sup>[15]</sup> Publications on soft-tissue augmentation are available in two-stage implantology but are lacking in IPIL protocols for dental implants.<sup>[16]</sup>

The purpose of this manuscript is to describe a procedure for soft-tissue augmentation at multiple tooth sites during IPIL dental surgery which was developed at a private oral implant centre in Bulgaria and to present follow-up results of its effectiveness.

## METHODOLOGY

### Patients

This retrospective study included data from 103 patients who underwent IPIL dental implant surgery at a private oral implant centre in Bulgaria, between June 2018 and July 2021. Clinical examination and cone-beam computed tomography were used to identify patients in need of connective tissue grafts (CTGs). Beginning with the third month after surgery, regular post-surgery evaluations of treatment outcomes were performed.

As a part of the internal evaluation process, we keep records of our patients' oral and related health aspects at each visit. The patients sign a consent form for the procedures they will be undergoing. Furthermore, we request their permission to use their data for scientific research and publications while their identities are concealed in accordance with the ethical principles outlined in the World Medical Association Declaration of Helsinki, revised in 2000 in Edinburgh. The need for ethical clearance was waived due to the retrospective nature of the study.

Applying the inclusion and exclusion criteria outlined below, we identified 53 patients who needed and received CTGs and 50 patients who did not need and did not receive CTGs during the IPIL implant surgery. The patients in the CTG group satisfied the following criteria: (1) at least two adjacent teeth extracted, (2) thin gingival biotype, (3) thin buccal bone phenotype, (4) advanced periodontitis and (5) signed informed consent form. Patients with intraoperative traumatic extractions, particularly of canines, were also included. The patients with advanced periodontitis had previously failed perio-treatments, resulting in extensive periodontal destruction.

The inclusion criteria for the group without CTGs were as follows: (1) at least two adjacent teeth extracted, (2) thick

gingival biotype, (3) thick buccal bone phenotype and (4) signed informed consent form. Patients with alveolar ridges that had already healed after extraction were not included in this group.

It is important to note that the goal of this study was not to compare patients with thin gingival biotypes to patients with thick gingival biotypes but to obtain clinically useful information about systematic outcomes that should be considered and further evaluated in our practice.

### Clinical procedures

The IPIL protocol was carried out using Basal Cortical Screw Ihde Dental GMBH one-piece corticobasal implants.<sup>[17]</sup> The thin and polished neck of these implants allows for immediate insertion into fresh extraction sockets in periodontally compromised patients.<sup>[18]</sup> The gingival margin is more coronally located, and the biologic width dimensions are more similar to those of natural teeth compared to two-piece submerged or non-submerged implants.<sup>[19]</sup>

### Harvesting the graft

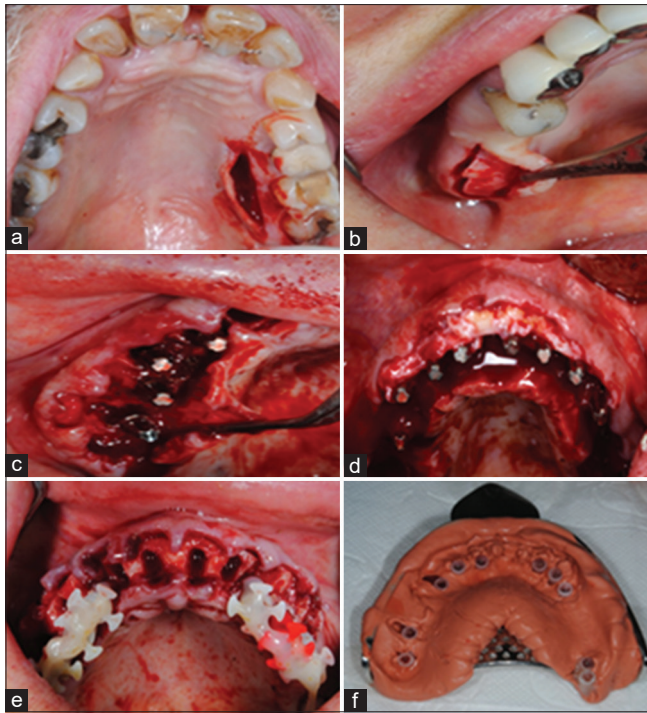
Connective tissue with different qualities can be harvested from the distolateral aspect of the palate, the maxillary tuberosity and the frontal palate. For optimal healing, these techniques aim to preserve a primary palatal flap, which is then sutured to the donor site after harvesting [Figure 1a].<sup>[20]</sup> The maxillary tuberosity [Figure 1b] is a promising alternative donor site to the lateral palate for soft-tissue harvesting, containing more lamina propria and less granular and adipose tissue than a CTG harvested from the deep lateral palate. Depending on the donor site, the graft can be taken before extractions (tuberosity or deep palate) or after the extractions and removal of the granulation tissue (anterior palate) [Figure 1c and d]. Before repositioning in the recipient bed, the graft must be kept in saline.

### Direct impression from the bone

The impression (PVS Express XT Penta Putty) is taken after the implants have been placed before positioning the graft and suturing the flap [Figure 1e]. The bone architecture after alveolectomy is recorded [Figure 1f] to provide the dental technician with a good orientation for the prosthesis–tissue relationship. As a rule, the prosthesis must be apically overcontoured with a clearance of 0.5 mm from the bone. During the healing process, additional remodelling-related bone reduction of around 1 mm is expected.

### Repositioning the graft

After harvesting, the graft is trimmed and shaped according to the recipient site. The graft is positioned in a way to cover the buccal-marginal part of the abutments [Figure 2a]. The buccal flap is released and coronally advanced to completely cover the graft [Figure 2b–d]. The sutures must be removed before the metal try-in, 48 h after the grafting procedure. The grafted site 72 h after surgery, just before the cementation of the metal-fused-to-ceramic (MFC) restoration, is shown in Figure 2e. The graft is placed in the area of 4-3-2-1-1-2-3-4.



**Figure 1:** (a) A single-incision technique to minimise the donor site morbidity, (b) An abundance of soft tissue in the tuberosity area that should be removed for better positioning of the abutment head, (c) An abundance of palatine keratinised tissue after removing the granulation tissue and trimming the thin bony spicules, (d) A buccally repositioned de-epithelised palatal graft, (e) The impression is taken after the placement of the implants, before positioning the graft and suturing the flap, (f) Precise bone architecture is recorded to give proper orientation for the technician for marginal overcontouring of the bridge

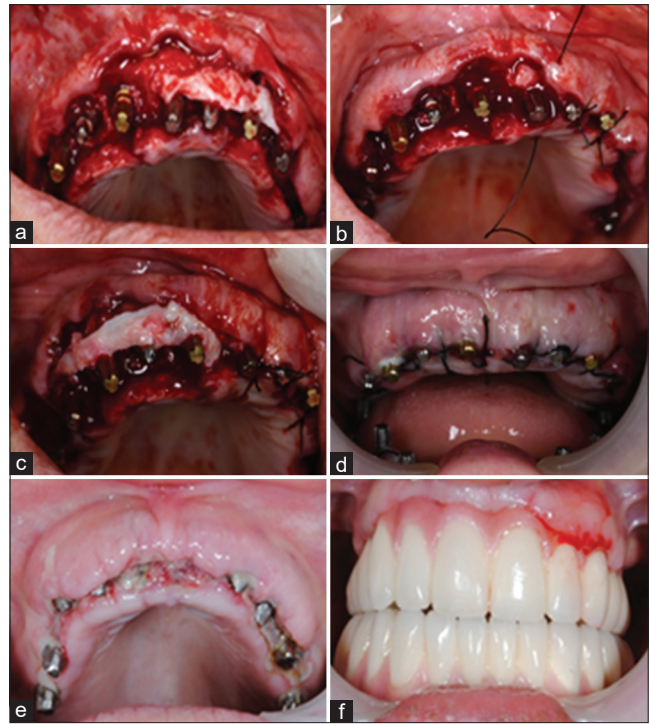
Figure 2f shows the clinical appearance of the grafted buccal gingiva immediately after the definitive cementation of the MFC bridge.

The photographs in Figure 3 are of a 47-year-old female patient with advanced periodontitis, a smoker, who had the following maxillary tooth area grafted: 5-4-3-2-2-3-4-5. At one year and six months postoperatively, a good adaptation of healthy augmented mucosa to the margins of the prosthesis was observed in the same patient [Figure 3a-c].

### Medication regimen

The surgical procedure, which includes extraction of teeth, implant placement and soft-tissue grafting, is performed under IV sedation (Dormicum 15 mg/3 ml and fentanyl 50 µg/ml, two ampoules). Infiltration anaesthesia is administered locally (Septanest 1/100,000 solution injection 68 mg/17 µg – 1.7 ml). To reduce post-operative inflammation and swelling, two ampoules of dexamethasone 4 mg/1 ml are administered intravenously during surgery.

The prosthetic phase (metal try, biscuit try and permanent porcelain fused to metal (PFM) bridge cementation) is performed under infiltration anaesthesia (Septanest 1/100,000 solution injection 68 mg/17 µg – 1.7 ml).



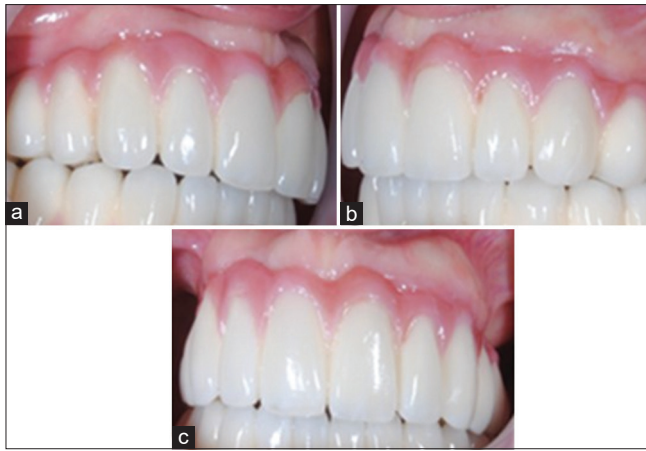**Figure 2:** (a) The graft is positioned in a way to cover the buccal-marginal part of the abutments, (b and c) The buccal flap is released and coronally advanced to completely cover the graft, (d) Post-operative view of the grafted site, (e) 72-h post-operative appearance of the grafted site before cementation of the MFC restoration, (f) The graft 3 days after the cementation of the MFC bridge. MFC: Metal-fused-to-ceramic

Oral antibiotics are prescribed for systemic antimicrobial prophylaxis (Avelo  $\times 400$  mg  $\times 7$  days). Irrigation with Betadine (povidone-iodine, 10%) is used for local intraoperative antimicrobial prophylaxis. Non-steroidal anti-inflammatory drugs (Nurofen Forte 400 mg, 1  $\times 8$  h) are prescribed for the next 15 days to control pain after surgery.

### Post-operative evaluation

At the implant dental clinic, where the patients were treated, we carry out regular assessments of the patients' implant and gingival health starting three months after surgery. Gingival recession can be evaluated in a variety of ways; however, in this case, we focused on post-operative metal exposure and gap formation, which are important clinical practice criteria due to patients' increasing demand for aesthetics in addition to functionality. The problems were identified through clinical examination and documented with clinical photographs as a part of the protocol adopted in our clinic [Figure 4]. The results were expressed with a binary variable where gingival recession (metal exposure and/or gap formation) was coded as 1 and its absence was coded as 0 at ten tooth extraction sites (15, 14, 13, 12, 11, 21, 22, 23, 24 and 25). Included are also data from the CTG patients' self-assessment of their gum health before and after the surgery, which is a part of the post-operative oral health-related quality of life questionnaire that our patients complete.





**Figure 3:** (a-c) 1-year and 6-month post-operative appearance, showing a good adaptation of healthy augmented mucosa to the margins of the prosthesis

### Statistical analysis

The statistical analyses were performed using SPSS version 27.0 (SPSS Inc., Chicago, IL, USA). The continuously measured variables (e.g. age and follow-up time) were screened for normality through the Shapiro–Wilk test. If normality was present, the results were described with the means and standard deviations. Relevant between-group comparisons were performed using the independent sample's *t*-test. In the absence of a normal distribution, the median values and the interquartile ranges were reported, and the Mann–Whitney *U*-test was used to compare the groups.

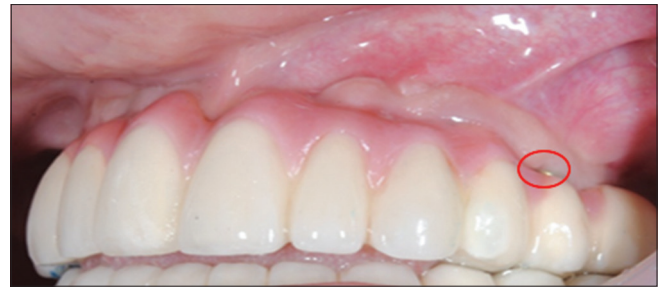The categorical variables were presented as frequencies and percentages (%), and associations were established through Fisher's exact test. A Spearman rank-order correlation analysis was performed to investigate the relationships between gum recession and patients' age, sex, smoking habits and follow-up time. The CTG patients' self-assessment of their gum health was presented on an ordinal scale, and the Wilcoxon paired-samples test was used to determine the change between before and after the surgery. All tests were two-tailed, and the results were considered statistically significant at  $P < 0.05$ .

## RESULTS

The two groups were similar on confounding factors such as patients' age ( $P = 0.302$ ), sex distribution ( $P = 0.085$ ), follow-up time ( $P = 0.631$ ), smoking habits ( $P = 0.845$ ) and diabetes ( $P = 0.496$ ) [Table 1].

### Soft-tissue augmentations in the connective tissue graft group

The mean number of grafted tooth sites in the CTG group was  $5 \pm 2.0$ . Based on the number of grafts received, the majority of the patients (56.60%) had six, seven or eight tooth sites grafted. A significant proportion of the 53 patients (87%) needed soft-tissue augmentation at the canine teeth (no. 13 and 23),  $P < 0.001$ . The lowest proportions of CTGs were



**Figure 4:** Gum recession around tooth number 25, revealing metal exposure and gap formation

performed at premolars no. 15 and no. 25 (26% and 15%, respectively). Indications for grafts at premolars no. 14 and no. 24 had 55% and 49% of the patients, respectively. Half of the patients (51%) needed CTGs at incisors no. 12 and no. 22, and 42% and 43% at incisors no. 11 and no. 21, respectively.

### Post-operative evaluation results

The follow-up assessment revealed a low incidence of gum recession in both the groups of patients, with slightly lower proportions in the group with CTGs, but no significant differences except regarding canine no. 13, where the incidence of gum recession was significantly higher in the group without CTGs,  $P = 0.016$ . The total proportion of gum recessions amounted to 12.60% in the group without CTGs versus 5.20% in the group without CTGs, with a significant difference,  $P < 0.001$  [Table 2].

The patients' age, sex, length of follow-up time or smoking habit were not significantly associated with the overall incidence of post-surgery gum recession [Table 3].

The CTG group experienced a significant reduction in the incidence of gum infections, swelling and bleeding, as well as pain and discomfort ( $P < 0.001$ ), with an improvement rate of 100%. A significant improvement in taste was reported with a positive change in 58.5% of the patients and no change in the remaining 41.50% ( $P < 0.001$ ). The patients' contentment with their gum health and appearance increased significantly ( $P < 0.001$ ), with 86.8% of them reporting very high satisfaction and 13.2% reporting high satisfaction [Table 4].

## DISCUSSION

We developed the procedure of soft-tissue augmentation at multiple tooth extraction sites during IPIL dental implant surgery in response to the growing importance of aesthetics in dental implantology. Its major advantage is that the buccal gingiva in the anterior maxilla is augmented simultaneously with tooth extraction and implant placement, thus achieving a harmonious blend of the implant-supported definitive prosthesis with the surrounding tissues. It also eliminates the need for the provisionalisation phase, reducing both treatment time and cost.<sup>[21]</sup>

As a part of the post-surgery follow-up plan, alongside the assessment of implant stability and efficiency, we also evaluated the patients' overall gum health and the incidence of post-operative

**Table 1: Background characteristics of the patients**

Variables	With connective tissue grafts ( <i>n</i> =53), <i>n</i> (%)	Without connective tissue grafts ( <i>n</i> =50), <i>n</i> (%)	<i>P</i>
Age (years)			
Mean±SD	53.09±8.53	54.90±9.12	0.302 <sup>t</sup>
Minimum–maximum	37–69	27–72	
Sex			
Male	24 (45.30)	31 (62.00)	0.115 <sup>f</sup>
Female	29 (54.70)	19 (38.00)	
Follow-up time, median (IQR)	16 (8)	16.50 (9)	0.631 <sup>U</sup>
Smoking			
Yes	28 (52.80)	25 (50.00)	0.845 <sup>f</sup>
No	25 (47.20)	25 (50.00)	
Diabetes			
Yes	2 (3.80)	0	0.496 <sup>f</sup>
No	51 (96.20)	50 (100)	

<sup>t</sup>Independent-samples *t*-test, <sup>f</sup>Fisher's exact test, <sup>U</sup>Mann–Whitney *U*-test. SD: Standard deviation, IQR: Interquartile range

**Table 2: Post-operative evaluation results**

Tooth sites	With connective tissue grafts ( <i>n</i> =53), <i>n</i> (%)	Without connective tissue grafts ( <i>n</i> =50), <i>n</i> (%)	<i>P</i>
Number 15			
No gum recession	13 (92.90)	40 (80.00)	0.431
Gum recession	1 (7.10)	10 (20.00)	
Number 14			
No gum recession	28 (96.60)	46 (92.00)	0.647
Gum recession	1 (3.40)	4 (8.00)	
Number 13			
No gum recession	45 (97.80)	41 (82.00)	0.016
Gum recession	1 (2.20)	9 (18.00)	
Number 12			
No gum recession	26 (96.30)	48 (96.00)	1.000
Gum recession	1 (3.70)	2 (4.00)	
Number 11			
No gum recession	22 (100)	48 (96.00)	1.000
Gum recession	0	2 (4.00)	
Number 21			
No gum recession	23 (100)	48 (96.00)	1.000
Gum recession	0	2 (4.00)	
Number 22			
No gum recession	24 (88.90)	47 (94.00)	0.659
Gum recession	3 (11.10)	3 (6.00)	
Number 23			
No gum recession	43 (93.50)	42 (84.00)	0.203
Gum recession	3 (6.50)	8 (16.00)	
Number 24			
No gum recession	23 (88.50)	42 (84.00)	0.739
Gum recession	3 (11.50)	8 (16.00)	
Number 25			
No gum recession	7 (87.50)	35 (70.00)	0.423
Gum recession	1 (12.50)	15 (30.00)	
Total			
No gum recession	254 (94.80)	437 (87.40)	0.001
Gum recession	14 (5.20)	63 (12.60)	

metal exposure and gap formation in the group with pre-operative CTG indications as well as in the group of patients with a thick gingival biotype and a thick buccal bone phenotype.<sup>[7,12-14]</sup>

Our findings revealed an overall low incidence of gum recessions in both the patient groups at the ten tooth sites where augmentations were performed in the CTG group, with

**Table 3: Spearman rank-order correlation results**

Variables	With connective tissue grafts (n=53)	Without connective tissue grafts (n=50)
Age		
Correlation coefficient ( $r^s$ )	0.065	0.112
P	0.642	0.440
Sex		
Correlation coefficient ( $r^s$ )	0.234	0.223
P	0.102	0.120
Follow-up time		
Correlation coefficient ( $r^s$ )	0.045	-0.115
P	0.749	0.427
Smoking		
Correlation coefficient ( $r^s$ )	-0.109	0.032
P	0.437	0.827

**Table 4: Change in gum-related oral health issues and overall satisfaction level in the 53 patients with connective tissue grafts**

Gum-related issues	Time	Responses					Paired Wilcoxon test	
		Persistent, n (%)	Frequent, n (%)	Occasional, n (%)	Rare, n (%)	None, n (%)	Percentage change	P
Infections, swelling, bleeding	Before surgery	10 (18.9)	15 (28.3)	15 (28.3)	13 (24.5)	0	+100	<0.001
	After surgery	0	0	0	7 (13.2)	46 (86.8)	=0.0	
							-0.0	
Pain, discomfort	Before surgery	0	10 (18.9)	25 (47.2)	12 (22.6)	6 (11.3)	+100	<0.001
	After surgery	0	0	2 (3.8)	3 (5.7)	48 (90.6)	=0.0	
							-0.0	
Negatively affected taste	Before surgery	2 (3.8)	6 (11.3)	16 (30.2)	10 (18.9)	19 (35.8)	+58.5	<0.001
	After surgery	0	0	0	5 (9.4)	48 (90.6)	=41.5	
							-0.0	
Level of satisfaction	Time	Responses					Paired Wilcoxon test	
		Very low	Low	Medium	High	Very high	Percentage change	P
Gum health appearance	Before surgery	19 (35.8)	23 (43.4)	8 (15.1)	3 (5.7)	0	+100	<0.001
	After surgery	0	0	0	7 (13.2)	46 (86.8)	=0.0	
							-0.0	

Plus (+): Improved, Equal (=): No change/sustained, Minus (-): Worsened

a slightly lower rate in the group with CTGs. Interestingly, we observed a significant difference between the two groups in gum recessions at canine no. 13. This tooth site was associated with the highest percentage of patients requiring gum augmentation in the CTG group, and the fact that it only had one patient (2.20%) with post-surgery gum recession is a good indicator of the procedure's success.

Furthermore, 18% of the patients in the group without CTGs showed gum recession at canine no. 13. This finding is not surprising because maxillary canines have been linked to a higher percentage of dehiscence than other anterior teeth, which may explain why post-operative gum recession occurs in some clinical cases.<sup>[22]</sup> In this line, the results from the group without CTG indications suggest that a CTG procedure may be considered even in patients with a thick tissue biotype in the areas around the canines.

It is also worth noting that the post-operative follow-up results in both the patient groups were robust in terms of age, gender, length

of follow-up time and smoking. This finding provides assurance of the procedure's efficacy regardless of risk factors such as smoking and older age.<sup>[23,24]</sup> Moreover, all 53 patients in the CTG group reported reductions in gum infections, swelling, bleeding and pain, as well as increased satisfaction with their gum health and aesthetics.

It should also be noted that the current findings cover a relatively short period. Furthermore, the study's retrospective design presupposes certain limitations, one of which is the lack of a true control group of patients with thin gingival biotypes who did not receive connective tissue grafting. Nonetheless, the described procedure builds on the existing practices and offers additional opportunities for achieving soft-tissue stability in specific periodontally compromised cases.

## CONCLUSION

Our findings and experience show that soft-tissue augmentation at multiple tooth extraction sites during IPIL dental implant

treatment has several advantages for patients who require implant-prosthetic rehabilitation and have advanced periodontitis, a thin gingival biotype and/or severe buccal bone damage. The most common benefits include an improved prosthesis–tissue interface in the aesthetic area and increased patient satisfaction due to the reduction in gum infections, swelling, bleeding and pain.

### Declaration of patient consent

The authors certify that they have obtained all appropriate patient consent forms. In the form, the patient(s) has/have given his/her/their consent for his/her/their images and other clinical information to be reported in the journal. The patients understand that their names and initials will not be published and due efforts will be made to conceal their identity, but anonymity cannot be guaranteed.

### Financial support and sponsorship

Nil.

### Conflicts of interest

There are no conflicts of interest.

## REFERENCES

- Chappuis V, Araújo MG, Buser D. Clinical relevance of dimensional bone and soft tissue alterations post-extraction in esthetic sites. *Periodontol 2000* 2017;73:73-83.
- Jung RE, Ioannidis A, Hammerle CH, Thoma DS. Alveolar ridge preservation in the esthetic zone. *Periodontol 2000* 2018;77:165-75.
- Liu Y, Li X, Jiang C, Guo H, Luo G, Huang Y, *et al.* Clinical applications of concentrated growth factors membrane for sealing the socket in alveolar ridge preservation: A randomized controlled trial. *Int J Implant Dent* 2022;8:46.
- Botticelli D, Berglundh T, Lindhe J. Hard-tissue alterations following immediate implant placement in extraction sites. *J Clin Periodontol* 2004;31:820-8.
- Araújo MG, Lindhe J. Dimensional ridge alterations following tooth extraction. An experimental study in the dog. *J Clin Periodontol* 2005;32:212-8.
- Fan Q, Zeng H, Fan W, Wu T, Sun J, Yan Q, *et al.* Ridge preservation of a novel extraction socket applying Bio-Oss® collagen: An experimental study in dogs. *J Dent Sci* 2021;16:831-9.
- Jafer MA, Salem RM, Hakami FB, Ageeli RE, Alhazmi TA, Bhandi S, *et al.* Techniques for extraction socket regeneration for alveolar ridge preservation. *J Contemp Dent Pract* 2022;23:245-50.
- Avila-Ortiz G, Chambrone L, Vignoletti F. Effect of alveolar ridge preservation interventions following tooth extraction: A systematic review and meta-analysis. *J Clin Periodontol* 2019;46 Suppl 21:195-223.
- Pinho MN, Roriz VL, Novaes AB Jr., Taba M Jr., Grisi MF, de Souza SL, *et al.* Titanium membranes in prevention of alveolar collapse after tooth extraction. *Implant Dent* 2006;15:53-61.
- Iasella JM, Greenwell H, Miller RL, Hill M, Drisko C, Bohra AA, *et al.* Ridge preservation with freeze-dried bone allograft and a collagen membrane compared to extraction alone for implant site development: A clinical and histologic study in humans. *J Periodontol* 2003;74:990-9.
- López-Pacheco A, Soto-Peñaloza D, Gómez M, Peñarrocha-Oltra D, Alarcón MA. Socket seal surgery techniques in the esthetic zone: A systematic review with meta-analysis and trial sequential analysis of randomized clinical trials. *Int J Implant Dent* 2021;7:13.
- Qahash M, Susin C, Polimeni G, Hall J, Wikesjö UM. Bone healing dynamics at buccal peri-implant sites. *Clin Oral Implants Res* 2008;19:166-72.
- Huynh-Ba G, Pjetursson BE, Sanz M, Cecchinato D, Ferrus J, Lindhe J, *et al.* Analysis of the socket bone wall dimensions in the upper maxilla in relation to immediate implant placement. *Clin Oral Implants Res* 2010;21:37-42.
- Kao RT, Fagan MC, Conte GJ. Thick vs. thin gingival biotypes: A key determinant in treatment planning for dental implants. *J Calif Dent Assoc* 2008;36:193-8.
- Buti J, Baccini M, Nieri M, La Marca M, Pini-Prato GP. Bayesian network meta-analysis of root coverage procedures: Ranking efficacy and identification of best treatment. *J Clin Periodontol* 2013;40:372-86.
- Bassetti M, Kaufmann R, Salvi GE, Sculean A, Bassetti R. Soft tissue grafting to improve the attached mucosa at dental implants: A review of the literature and proposal of a decision tree. *Quintessence Int* 2015;46:499-510.
- Lazarov A. Immediate Functional loading: Results for the concept of the strategic implant (®). *Ann Maxillofac Surg* 2019;9:78-88.
- Palka LR, Lazarov A. Immediately loaded bicortical implants inserted in fresh extraction and healed sites in patients with and without a history of periodontal disease. *Ann Maxillofac Surg* 2019;9:371-8.
- Hermann JS, Buser D, Schenk RK, Schoolfield JD, Cochran DL. Biologic width around one- and two-piece titanium implants. *Clin Oral Implants Res* 2001;12:559-71.
- Puri K, Kumar A, Khatri M, Bansal M, Rehan M, Siddeshappa ST. 44-year journey of palatal connective tissue graft harvest: A narrative review. *J Indian Soc Periodontol* 2019;23:395-408.
- Van Nimwegen WG, Goené RJ, Van Daelen AC, Stellingsma K, Raghoobar GM, Meijer HJ. Immediate implant placement and provisionalisation in the aesthetic zone. *J Oral Rehabil* 2016;43:745-52.
- Jorgić-Srdjak K, Plancak D, Bosnjak A, Azinović Z. Incidence and distribution of dehiscences and fenestrations on human skulls. *Coll Antropol* 1998;22 Suppl:111-6.
- Kanmaz M, Kanmaz B, Buduneli N. Periodontal treatment outcomes in smokers: A narrative review. *Tob Induc Dis* 2021;19:77.
- Kanmaz MG, Kanmaz B, Buduneli N. Gingival recession and root coverage outcomes in smokers. *Popul Med* 2022;26:1-12.